

Orofacial Gangrene (Noma/Cancrum) – Tale of Orofacial Devastation

Asish Rajasekharan¹, Sherin Ann Thomas², Twinkle S Prasad³, Vinimol Chandini⁴, Anita Balan⁵

Author's Affiliation: ¹Associate Professor and Head, ²Assistant Professor, Department of Oral Medicine & Radiology, Government Dental College, Alappuzha, Vandanam, Kerala 688005, India. ³Associate Professor, Dept. of Oral Medicine & Radiology, Government Dental College, Gandhinagar, Kottayam, Kerala 686008, India. ⁴Assistant Professor, Department of Pharmacology, Government Medical College, Kollam, Kerala 691574, India. ⁵Principal, Government Dental College, Chalakkuzhi, Thiruvananthapuram, Kerala 695011, India.

Corresponding Author: Asish Rajasekharan, Associate Professor and Head, Department of Oral Medicine & Radiology, Government Dental College, Alappuzha, Vandanam, Kerala 688005, India.

E-mail: asishrajasekharan12@gmail.com

Received on 17.10.2019; Accepted on 13.11.2019

How to cite this article:

Asish Rajasekharan, Sherin Ann Thomas, Twinkle S Prasad, et al. Orofacial Gangrene (Noma/Cancrum) – Tale of Orofacial Devastation. Indian J Dent Educ. 2019;12(4):147-150.

Abstract

Cancrum oris is an orofacial gangrene, which causes destruction of the infected tissues which destroys the soft and hard tissues of the oral and para-oral structures. The disease mainly occurs in children having malnutrition, poor oral hygiene and debilitating illness. Noma requires infection by a consortium of microorganisms, with *Fusobacterium necrophorum* and *Prevotella intermedia* as the suspected key players. Without appropriate treatment, the mortality rate from noma is 70–90%.

Keywords: Noma; Cancrum oris; Necrotizing ulcerative stomatitis.

Introduction

Cancrum oris or noma from the Greek nomein “to devour”.¹ It is a gangrenous stomatitis of the mouth, soft and hard tissues of the face especially in children. The resulting dehumanizing orofacial gangrene may involve the mandible, maxilla, and nose, and it occasionally extends to the infraorbital margins. If not treated, noma is fatal.² Noma has disappeared from the industrialized countries since the 20th century, but is common in the third world especially in Africa.³ Since the disease process starts from within the oral cavity and spreads outward, the intraoral destruction is generally more extensive

than the externally visible grotesque disfigurement.

The exact cause of the disease is still not known. The poor oral hygiene in children, oral nutrition, weak immune system, past history of tuberculosis, malignancy and HIV are predisposing factors of noma.⁴⁻⁶ The disease is not communicable.

It is postulated that the disease is triggered by a consortium of microorganism including *Fusobacterium necrophorum*.^{7,8} which elaborates several dermo necrotic toxic metabolites. It is acquired by the impoverished children via fecal contamination, resulting from shared residential facilities with animals and very poor environmental sanitation. Other common pathogens found

are *Prevotella intermedia*, *Borrelia vincentii*, fusiform bacilli, non-hemolytic streptococci and staphylococci. Anaerobic bacteria may be present in rapidly progressing disease.⁹⁻¹¹

Noma causes sudden, rapidly progressive tissue destruction. If untreated, the disease is rapidly fatal. The sequelae of noma depend largely on the anatomic sites of the lesion, the extent and severity of tissue destruction, and the stage of development of the dentition and facial skeleton prior to onset of the disease.

Here a case of cancrum oris presented to our department is being discussed.

Case Report

A 65-year-old female patient came to the department of Oral Medicine & Radiology, Government Dental College, with complaints of pain in the mouth for period of 1 month. She revealed the history of diabetes mellitus and hypertension for a period of 15 years and is under treatment (Fig. 1). The rest of the history was non contributory. Intraoral examination revealed the presence of enlarged erythematous areas of maxillary anterior gingiva

with smooth shiny and rolled out margins, loss of stippling and blunt interdental papilla (Fig. 2). On palpation these areas were soft and bled easily. On the hard palate region multiple ulcerations were scattered across the midline with varying sizes and shapes irregular margins and floor covered with necrotic slough (Fig. 3). No specific discharge was noted from the ulcer. The surrounding mucosa appeared erythematous. On palpation these areas were tender with sloping edges and non indurated base. Regional lymph nodes enlarged and reactive lymphadenopathy was noticed. Dorsum of tongue shows white coated appearance scrapable with tongue blade suggestive of oral candidiasis (Fig. 4). Based on the history and clinical examination provisional diagnosis of cancrum oris was made.

Ulcerative lesions like those in nutritional deficiency states, malignant oral lesions and manifestations of syphilis-gumma were considered for the differential diagnosis. Both intraoral and extraoral radiographs were taken. Cross sectional maxillary occlusal radiograph revealed tooth floating in air appearance in maxillary anterior region which was further confirmed with panoramic radiograph. The final diagnosis was established with noma or cancrum oris (Figs. 5, 6).

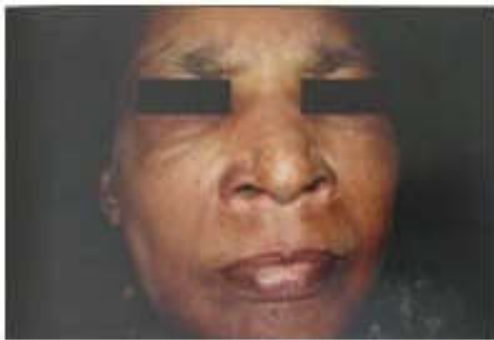

Fig. 1: Facial photograph.

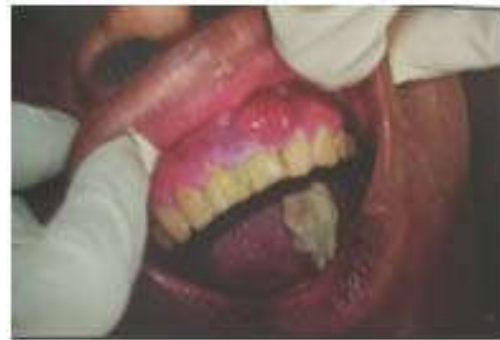

Fig. 2: Intraoral photograph showing enlarged erythematous areas in maxillary anterior gingiva.

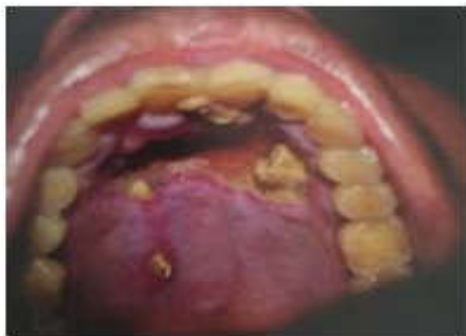

Fig. 3: Intraoral photograph showing necrotic areas in palate.

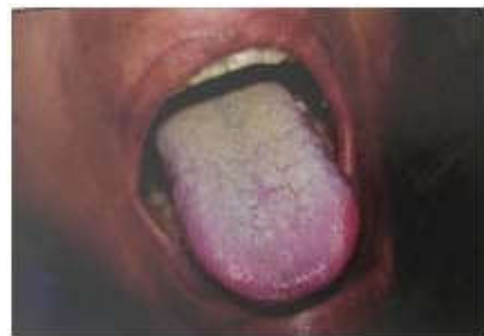

Fig. 4: Candidiasis on dorsum of tongue.

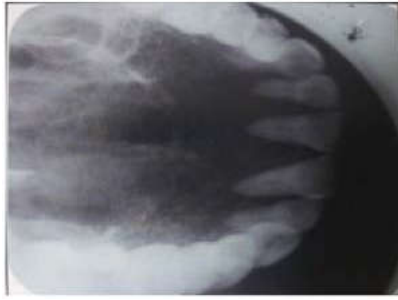

Fig. 5: Occlusal radiograph shows destructive areas on palate.

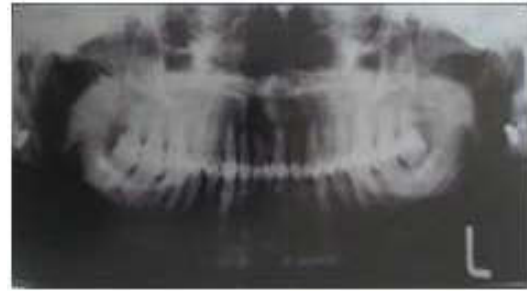


Fig. 6: Panoramic view.

Discussion

The epidemiology of noma has not changed much over the years, except that there has been a reduction in the mortality rate from 90% to about 8% to 10%, mainly because of modern antibiotics. The mucous membranes of gums, lining of cheeks become inflamed and develop an ulcer.¹⁻⁴ The infection spreads from the mucous membranes to the skin thus causing necrosis of the tissues of lips and cheeks. There is sore mouth with focal edema having fetid odor and taste.⁴⁻⁶ Foul smelling, purulent oral discharge is associated with profuse salivation, anorexia with cervical lymphadenopathy.^{7,8}

First there appears a tender, small purplish red spot on the gingiva, which quickly becomes indurated, ulcerated and then becomes necrotic with associated edema. It forms a bluish black necrotic cone-shaped mass.⁸⁻¹¹ There is rapid progression to gangrene during the next 4 to 72 hours. The involvement can be uni or bilateral and may affect any part of the face including upper/lower jaw. It may produce extensive facial mutilation with loss of intraoral structures and functions. Rapid, painless tissue break down continues and this gangrenous process can destroy the soft tissues and even the bone.

The management of noma requires a multidisciplinary team approach.¹² In the early stages will need oral irrigation with hydrogen peroxide, saline and 0.2% chlorhexidine, thus helps to slough the necrotic tissue. Adequate hydration, correction of electrolytes and vitamin deficiencies with provision of sufficient nutritional support is essential, even through nasogastric tube, if necessary. In most cases we need to recommend penicillin plus metronidazole to cover predominant organisms. Medication needs to be continued for at least 14 days. The use of antibiotic may cause

candidal overgrowth, thus requires antifungal coverage. Late stage treatment requires plastic/reconstruction surgery for correction of extensive facial mutilation. To prevent noma, measures to improve nutrition, cleanliness and sanitation and early vaccination is required.

Conclusion

Noma (also known as cancrum oris) is a rapidly progressive often gangrenous infection of the mouth and face. The disease is associated with high morbidity and mortality rates, so careful follow up is required for every patient.

References

- Berthold P. Noma. A forgotten disease. *Dent Clin North Am* 2003;47:559-74.
- Tempest NN. Cancrum oris. *Br J Surg* 1966;53: 949-69.
- Adolph HP, Yugueros P, Woods JE. Noma: A review. *Ann Plast Surg* 1996;37:657-68.
- Marck KW. A history of noma, the face of poverty. *Plast Reconstr Surg* 2003;111:1702-7.
- Enwonwu CO, Falkler WA Jr, Idigbe EO, et al. Noma (cancrum oris) questions and answers. *Oral Dis* 1999;5:144-9.
- Yuca K, Yuea SA, Cankaya H et al. Report of an infant with noma (cancrum oris). *J Dermatol* 2004;31:488-91.
- Falkler WA Jr, Enwonwu CO, Idigbe EO. Isolation of *Fusobacterium necrophorum* from cancrum oris (noma). *Am J Trop Med Hyg* 1999;60:150-6.
- Falkler WA Jr, Enwonwu CO, Idigbe EO. Microbial understanding and mysteries of noma (cancrum oris). *Oral Dis* 1999;5:150-5.
- Enwonwu CO, Falkler WA Jr, Idigbe EO et al. Pathogenesis of cancrum oris (noma):

- confounding interactions of malnutrition with infection. *Am J Trop Med Hyg* 1999;60:223-32.
10. Paster BJ, Falkler WA Jr, Enwonwu CO et al. Prevalent bacterial species and novel phylotypes in advanced noma lesions. *J Clin Microbiol* 2002;40:2187-91.
 11. Brady-West DC, Richards L, Thame J et al. Cancrum oris (noma) in a patient with acute lymphoblastic leukemia. A complication of chemotherapy induced neutropenia. *West Indian Med J* 1998;47:33-4.
 12. Adekeye EO, Ord RA. Cancrum oris: Principles of management and reconstructive surgery. *Br J Surg* 1983;4:149-94.
-
-
-